

Rare pleural tumor mistaken for post-COVID-19 syndrome

Natalia Maria Kwiatkowska, Alicja Kamińska, Magdalena Sielewicz, Mariusz Kasprzyk, Cezary Piwkowski

Department of Thoracic Surgery, Poznan University of Medical Sciences, Poznan, Poland

Submitted: 14 September 2023

Accepted: 19 December 2023

Arch Med Sci Civil Dis 2023; 8: e47–e49

DOI: <https://doi.org/10.5114/amsd/177334>

Copyright © 2023 Termedia & Banach

Corresponding author:

Natalia Maria Kwiatkowska

Department of

Thoracic Surgery

Poznan University

of Medical Sciences

Poznan, Poland

E-mail: natalia.maria.

kwiatkowska@gmail.com

Up to this date, according to the World Health Organization, the COVID-19 pandemic has resulted in more than 770 million confirmed cases of COVID-19, including 6.9 million deaths [1]. While the gold standard for diagnosing COVID-19 remains the polymerase chain reaction (PCR), more commonly clinicians use X-ray or computed tomography (CT) to assess the extent of the disease or to track ongoing COVID-19 infection [2]. This opens up an opportunity to reveal some incidental findings such as emerging lung cancer, or as it was in our case, pleural tumor. Solitary fibrous tumors of the pleura (SFTPs) represent only 5% of pleural tumors [3]. They are usually benign, however, about 10–20% can become malignant [4]. SFTPs can occur at any age but are typically present in the sixth and seventh decades of life with no gender preference [4]. The underlying cause of SFTP is still unknown. No proven correlation exists with exposure to asbestos, tobacco smoke, or air pollution [5]. SFTPs are usually asymptomatic in the early stages. However, large tumors can cause symptoms like cough, chest pain, chest tightness, and dyspnea due to the compression of surrounding tissues. Complete surgical resection is the treatment of choice for both benign and malignant varieties and can be performed safely without a preoperative diagnosis [5]. After complete surgical resection, the risk of recurrence ranges from < 2% in benign SFTPs to 63% in malignant tumors [6].

A 60-year-old female was referred in critical condition to the Department of Thoracic Surgery to treat a large tumor filling the right half of the chest cavity. Her medical history revealed arterial hypertension, hypothyroidism, and a history of COVID-19 infection. The patient presented with dyspnea requiring oxygen therapy, chest pain, and peripheral edema. Moreover, since her COVID-19 illness, she has been experiencing progressive weakness, shortness of breath, sporadic productive cough, and significant loss of weight for over a year (Figure 1).

The lesion was detected in a chest X-ray due to the worsening symptoms and presented as total opacification of the right lung. Computed tomography (CT) of the chest showed a mass in the right hemithorax with complete lung atelectasis and mediastinal shift to the left. Bronchoscopy did not reveal endobronchial invasion. A CT-guided core needle biopsy was performed. Histopathological examination of a specimen revealed a mesenchymal neoplasm with uncertain malignant potential. Due to the severe manifestation and the lack of other treatment options, the patient was qualified for urgent surgery. A 7 kg tumor with

32.0 × 24.0 × 11.5 cm dimensions was resected via a right antero-latero-posterior thoracotomy. Complete curative excision of the tumor, with free resection margins was performed, and complete re-expansion of the lung was observed.

The final histopathological examination reported the malignant form of a solitary fibrous tumor of the pleura. The surgery relieved the patient's symptoms, and we observed significant clinical improvement during hospitalization. The patient remains disease-free.

We present the case of a woman, which highlights therapeutic dilemmas associated with a new onset of developing malignancy within the chest, particularly in the backdrop of a global pandemic that has redefined the approach to respiratory symptoms. While SFTPs account for a mere 5% of pleural tumors, their clinical presentation can overlap considerably with more common respiratory conditions, including COVID-19, as demonstrated by this case showing initial misdiagnosis, primarily attributing the symptoms to long COVID-19 syndrome.

The symptoms described such as dyspnea, shortness of breath, and productive cough are common to both COVID-19 and pleural or lung tumors. In the high-stakes environment of a pan-

demic, where quick diagnostic and treatment decisions are often required, it is understandable but regrettable that a more uncommon diagnosis was initially overlooked. Liang *et al.* showed that around 1% of patients with COVID-19 infection also had a history of cancer, and among them, lung cancer was the most prevalent one [7].

The patient's medical history further complicated the diagnosis, making it easier to attribute these chronic symptoms to long-term COVID-19, possible interstitial lung disease, or another more common respiratory illness, like viral pneumonia due to influenza. The patient's history of COVID-19 initially skewed the diagnostic lens towards long COVID, especially given the epidemiology suggesting that approximately 10-30% of adults recovering from acute COVID-19 will experience some form of lingering symptoms. However, the persistence and exacerbation of respiratory symptoms beyond what is typically observed in long-term COVID cases should trigger additional investigations, especially imaging studies, as demonstrated by our patient's case.

The rarity of SFTPs makes them an infrequently considered differential diagnosis. While benign SFTPs generally have an excellent prognosis following surgical resection, the malignant variety

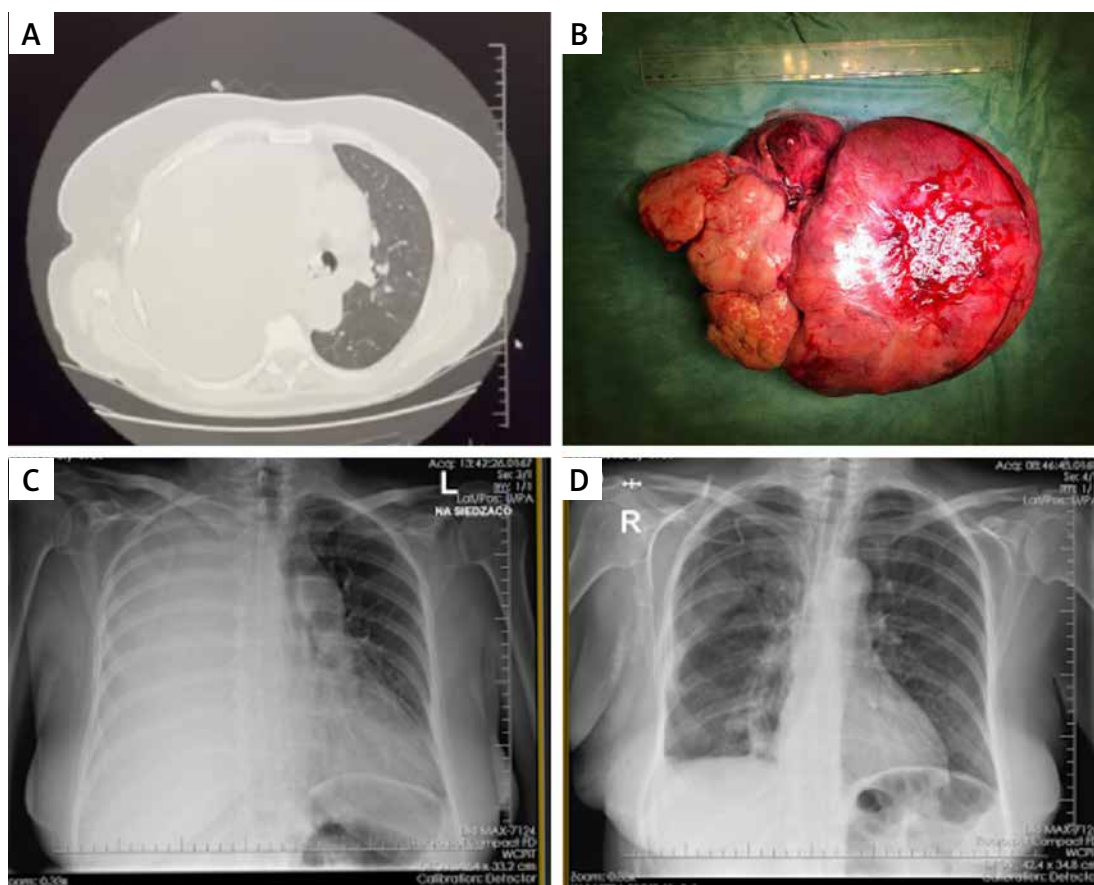


Figure 1. A – Mass in the right hemithorax with complete lung atelectasis and mediastinal shift to the left. B – A 7 kg tumor with 32.0 × 24.0 × 11.5 cm dimensions. An X-ray performed before (C) and after (D) the surgery

can be more unpredictable, further emphasizing the importance of early diagnosis and intervention. As per the available literature, the epidemiology of SFTPs shows no predilection for gender or race, but the age of presentation often varies [5]. Most patients are 50-70 years old, aligning with our 60-year-old female patient. Our patient showed considerable clinical improvement post-operatively, consistent with the literature suggesting that complete resection often results in a favorable outcome, even in malignant cases.

In conclusion, this case serves as a reminder for clinicians to consider a broader range of differential diagnoses for respiratory symptoms, even in the age of COVID-19. Early detection and surgical intervention are paramount, particularly with SFTPs and other rare lung or pleural tumors. While COVID-19 will continue to dominate medical practice for the foreseeable future, this case illustrates that other severe, non-COVID respiratory illnesses remain a vital consideration. Even as we navigate this new normal, the fundamentals of medical practice – such as thorough diagnostic evaluation and a broad differential diagnosis – remain as crucial as ever.

Conflict of interest

The authors declare no conflict of interest.

References

1. WHO Coronavirus (COVID-19) Dashboard [Internet]. [cited September 9, 2023]. Available at: <https://covid19.who.int>
2. Costa YMG, Silva SA, Teixeira LO, et al. COVID-19 detection on chest X-ray and CT scan: a review of the top-100 most cited papers. *Sensors* 2022; 22: 7303.
3. Mendez-Sanchez H, Mendez-Vivas W, Vargas-Mendoza GK, Vazquez-Lopez S, Williams-Jacquez AD, Cortes-Telles A. Solitary fibrous tumors of the pleura: a clinical-pathological characterization emphasizing changes in lung function. *Adv Respir Med* 2019; 87: 247-51.
4. Robinson LA. Solitary fibrous tumor of the pleura. *Cancer Control* 2006; 13: 264-9.
5. Magdeleinat P, Alifano M, Petino A, et al. Solitary fibrous tumors of the pleura: clinical characteristics, surgical treatment and outcome. *Eur J Cardiothorac Surg* 2002; 21: 1087-93.
6. Tan JHY, Hsu AAL. Challenges in diagnosis and management of giant solitary fibrous tumor of pleura: a case report. *BMC Pulm Med* 2016; 16: 114.
7. Liang W, Guan W, Chen R, et al. Cancer patients in SARS-CoV-2 infection: a nationwide analysis in China. *Lancet Oncol* 2020; 21: 335-7.