

Experimental research

A study to reveal the effectiveness of taxifolin in sunitinib-induced oxidative muscle damage in rats

Hasan Yaşar¹, Ceyda Tanoglu¹, Mine Gulapoglu², Halis Suleyman³, Gülce Naz Yazıcı⁴, Yusuf Kemal Arslan⁵

¹Department of Neurology, Medicine Faculty, Erzincan Binali Yıldırım University, Erzincan, Turkey

²Department of Biochemistry, Erzurum Atatürk University, Turkey

³Department of Pharmacology, Erzincan Binali Yıldırım University, Erzincan, Turkey

⁴Department of Histology, Erzincan Binali Yıldırım University, Erzincan, Turkey

⁵Department of Biostatistics, Erzincan Binali Yıldırım University, Erzincan, Turkey

Submitted: 4 May 2021

Accepted: 28 July 2021

Arch Med Sci Civil Dis 2021; 6: e103–e108

DOI: <https://doi.org/10.5114/amsd.2021.109242>

Copyright © 2021 Termedia & Banach

Corresponding author:

Hasan Yaşar

Medicine Faculty

Erzincan Binali

Yıldırım University

Erzincan, Turkey

Phone: 05056315719

E-mail: yasar_hsan@hotmail.com

com

Abstract

Introduction: The aim of this study is to examine the oxidative damage caused by sunitinib on skeletal muscle and whether taxifolin is effective against that oxidative damage.

Material and methods: Thirty albino Wistar male rats were used in the experiment. The rats were divided into 3 equal-sized groups: a sunitinib-only administered group (SUN), a sunitinib + taxifolin administered group (SUT), and a control group (CG) without treatment. Taxifolin and sunitinib were administered by oral gavage at a dose of 50 mg/kg for taxifolin and a dose of 25 mg/kg for sunitinib. Striated hind limb muscle tissue of rats was removed; malondialdehyde (MDA), reduced glutathione (GSH), and superoxide dismutase (SOD) levels were measured in muscle tissue; muscle tissue was examined histopathologically; creatine kinase (CK) levels were determined in the blood samples of rats; and the results were compared between the groups.

Results: In the SUN group, MDA and CK values were statistically significantly higher than in the SUT and CG groups, but SOD and GSH values were statistically significantly lower. The SUT and CG groups were similar when compared. Histopathologically, congested blood vessels, oedema, degeneration, inflammation, and rupture of muscle fibres in muscle tissue were detected in the SUN group. However, in the SUT group it was observed that blood vessels were normal, there were no degenerative findings, and inflammation was resolved.

Conclusions: Sunitinib causes oxidative damage to skeletal muscle tissue. Taxifolin prevents the toxic effect of sunitinib on skeletal muscle due to its antioxidant effects.

Key words: skeletal muscle, sunitinib, oxidative damage, taxifolin.

Introduction

Sunitinib (Sutent; Pfizer, New York, NY) is a new oral multityrosine kinase inhibitor with antitumour and antiangiogenic activities. Sunitinib is approved in clinics for the treatment of advanced renal cell carcinoma and gastrointestinal stromal tumours [1, 2]. Sunitinib inhibits vascular endothelial growth factor receptor (VEGFR) 1–3, platelet-associated growth factor

receptor (PDGFR) α , stem-cell growth factor receptor, fms-associated tyrosine kinase receptor (flt3) 3, and colony-stimulating factor 1 receptors. Furthermore, it suppresses angiogenesis and proliferation in tumour cells [3].

Although its anti-cancer effect is more specific compared to other chemotherapeutic drugs, sunitinib is not selective [1, 4]. Cardiac and skeletal muscle toxicity has been noted among its adverse effects on many organs during its use [5]. Toxic effects due to chemotherapeutic drugs adversely affect patients' quality of life. The toxic effect of sunitinib on skeletal muscle means that the dose of sunitinib is decreased in patient treatment [5, 6]. The effects of chemotherapy on skeletal muscle have been proven to persist for many years after cessation of treatment and are not associated with factors that lead to cancer-induced cachexia [5]. It is thought that revealing the toxic effect mechanism that occurs during chemotherapy will provide the treatment for the pathogenesis of this effect. It has been suggested that the side effects caused by sunitinib are mainly related to toxic effects on mitochondria [7]. Drugs that disrupt mitochondrial functions cause the depletion of adenosine triphosphate (ATP) stores and ultimately lead to mitochondrial dysfunction. Inhibition of 5' adenosine monophosphate-activated protein kinase (AMPK) pathway is one of the mechanisms mediating mitochondrial toxicity [4, 7]. Not only functional impairment but also lipid oxidation has been detected in skeletal muscle [5]. Excessive production of reactive oxygen species (ROS) in mitochondria causes mitochondrial deoxyribonucleic acid (mtDNA) damage, muscle dysfunction, and atrophy as a result of damage to mitochondria in muscle tissue [5, 8]. It is assumed that the skeletal muscle toxicity of sunitinib is caused by a decrease in ATP and an increase in ROS production [9]. This suggests that oxidative stress plays a role in the pathogenesis of skeletal muscle toxicity caused by sunitinib and that antioxidants can be useful in its treatment.

Taxifolin (3,5,7,3,4-pentahydroxy flavanone or dihydroquercetin) is an abundant flavonoid in citrus fruits and onions [10]. Flavonoids display their antioxidant activity by inhibiting the enzymatic reactions responsible for lipid peroxidation and the formation of free radicals [11]. Taxifolin is both a powerful antioxidant and a powerful flavonoid. Studies have shown that in muscle cells, taxifolin inhibits ROS formation, mitochondrial damage, and apoptosis [12, 13].

Therefore, the aim of this study is to investigate the biochemical and histopathological effects of taxifolin against oxidative skeletal muscle damage caused by sunitinib in rats.

Material and methods

Study animals

A total of 30 male albino Wistar rats weighing 258–266 g were used in the experiment. All the rats were obtained from Atatürk University Medical Experimental Practice and Research Centre. Animals were housed and fed under suitable conditions at room temperature (22°C) in a suitable laboratory environment. Before the experimental study, ethical permission was obtained from the related institution of Atatürk University (Ethical Committee of Ataturk University, Number: 1800266280, Date: 20.09.2018).

Chemical substances

The following chemical substances were used for the experiments: sunitinib, thiopental sodium, and taxifolin, provided by Pfizer, İE Ulagay (Turkey), and Evalar (Russia), respectively.

Experiment groups and procedure

The rats were grouped as follows: a sunitinib-only group (SUN), a sunitinib + taxifolin group (SUT), and a control group without any treatment (CG). Taxifolin, sunitinib, and normal saline (0.9% NaCl) were administered by oral gavage. Taxifolin was administered at a dose of 50 mg/kg [14] to the SUT ($n = 10$) group of rats. An equivalent volume of normal saline was administered to the SUN ($n = 10$) and CG ($n = 10$) groups. One hour after administration of taxifolin and saline, sunitinib was administered at doses of 25 mg/kg [15] to the SUT and SUN groups by the same method. This procedure was repeated once a day for 5 weeks. At the end of this period, the animals were then euthanized by decapitation with high-dose thiopental sodium anaesthesia. Subsequently, muscle tissue was accessed by skin incision under sterile conditions. Finally, 1.5 cm of hind limb striated muscle tissue was cut out with surgical scissors. Malondialdehyde (MDA), reduced glutathione (GSH), and superoxide dismutase (SOD) levels were measured in the extracted muscle tissue of the animals. Creatine kinase (CK) activity was determined in blood samples taken from the tail veins before the animals were euthanized. Muscle tissue was also examined histopathologically.

Biochemical analyses

Prior to dissection, all tissues were rinsed with phosphate-buffered saline solution. The tissues were homogenized in ice-cold phosphate buffers (50 mM, pH 7.4) that were appropriate for the variable to be measured. The tissue homogenates were centrifuged at 10,000 rpm for 20 min at 4°C,

and the supernatants were extracted to analyse MDA, GSH, and SOD. All tissue results were expressed by dividing to g protein. All spectrophotometric measurements were performed via a microplate reader (Bio-Tec, USA).

Malondialdehyde (MDA) analysis

MDA measurements were based on the method used by Ohkawa *et al.*, involving spectrophotometric measurement of absorbance of the pink-coloured complex formed by thiobarbituric acid (TBA) and MDA. The tissue-homogenate sample (25 µl) was added to a solution containing 25 µl of 80 g/l sodium dodecyl sulphate and 1 ml mixture solution (200 g/l acetic acid + 1.5 ml of 8 g/l 2-thiobarbiturate) [16]. The mixture was incubated at 95°C for 1 h. Upon cooling, 1 ml of n-butanol/pyridine (15 : 1) was added. The mixture was vortexed for 1 min and centrifuged for 10 min at 4000 rpm. The absorbance of the supernatant was measured at 532 nm. The standard curve was obtained by using 1,1,3,3-tetramethoxypropane.

Reduced glutathione (GSH) analysis

GSH measurements were performed according to method of Sedlak J and Lindsay RH. DTNB (5,5'-dithiobis [2-nitrobenzoic acid]) disulphide is chromogenic in the medium, and DTNB is reduced easily by sulphhydryl groups [17]. The yellow colour produced during the reduction was measured by spectrophotometry at 412 nm. For measurement, a cocktail solution (5.85 ml 100 mM Na-phosphate buffer, 2.8 ml 1 mM DTNB 3.75 ml 1 mM NADPH, and 80 µl 625 U/l Glutathione reductase) was prepared. Before measurement, 0.1 ml meta-phosphoric acid was added to 0.1 ml tissue homogenate and centrifuged for 2 min at 2000 rpm for deproteinization. The 0.15 ml cocktail solution was added to 50 µl of supernatant. The standard curve was obtained using GSSG.

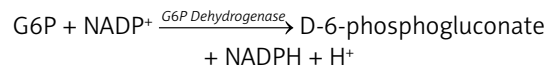
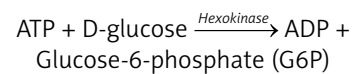
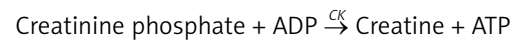
Superoxide dismutase (SOD) analysis

SOD measurements were performed according to the method of Sun *et al.* [18]. When xanthine is converted into uric acid by xanthine oxidase, SOD forms. If nitro blue tetrazolium (NBT) is added to this reaction, SOD reacts with NBT, and a purple-coloured formazan dye occurs. The sample was weighed and homogenized in 2 ml of 20 mmol/l phosphate buffer containing 10 mmol/l EDTA at pH 7.8. The sample was centrifuged at 6000 rpm for 10 min, and then the brilliant supernatant was used as the assay sample. The measurement mixture containing 2450 µl measurement mixture (0.3 mmol/l xanthine, 0.6 mmol/l EDTA, 150 µmol/l NBT, 0.4 mol/l Na₂CO₃, 1 g/l bovine serum albumin), 500 µl supernatant and

50 µl xanthine oxidase (167 U/l) was vortexed. It was then incubated for 10 min. At the end of the reaction, formazan occurred. The absorbance of the purple-coloured formazan was measured at 560 nm. As more of the enzyme exists, there is less O₂⁻ radical that reacts with NBT.

Creatine kinase (CK) determination

Creatine kinase determination in plasma obtained from animals was measured photometrically in the Roche/Hitachi cobas c 701 systems. Using ready-made test reagents, all steps of the test were carried out in accordance with the procedure. The UV test is applied according to the following reactions:



Equimolar amounts of NADPH and ATP are formed at the same rate. The rate of NADPH formation measured photometrically at 340 nm is directly proportional to the CK activity.

Histopathological examination

All the tissue samples were first identified in a 10% formaldehyde solution for light microscope assessment. Following the identification process, tissue samples were washed under tap water in cassettes for 24 h. Samples were then treated with conventional grade of alcohol (70%, 80%, 90%, and 100%) to remove the water within tissues. Tissues were then passed through xylol and embedded in paraffin. Four-to-five-micron sections were cut from the paraffin blocks and haematoxylin-eosin staining was administered. Their photos were taken following the Olympus DP2-SAL firmware program (Olympus® Inc. Tokyo, Japan) assessment. Histopathological assessment was carried out by a pathologist blind for the study groups.

Statistical analysis

The results are presented for continuous variables as mean ± standard deviation (SD), median, and minimum–maximum. The normality of distribution for continuous variables was confirmed with the Shapiro-Wilk test. For comparison of independent continuous variables between the 3 groups, analysis of variance (ANOVA) was used. Homogeneity of variances was confirmed with Levene's test. While comparing 2 groups, Tukey or Games-Howell was used as a post-hoc test. The statistical level of significance for all tests was considered to be 0.05.

Table I. Biochemical results in the study groups

Parameter	SUN	SUT	CG	P-value
MDA	5.0 ±0.3 ^a 4.9 (4.6–5.6)	2.4 ±0.4 ^b 2.3 (2.0–3.1)	2.0 ±0.1 2.1 (1.8–2.2)	< 0.001
GSH	2.0 ±0.5 ^a 2.2 (1.2–2.6)	5.1 ±0.7 ^b 5.4 (4.0–6.0)	5.9 ±0.6 5.9 (5.1–6.8)	< 0.001
SOD	16.3 ±2.7 ^a 16.5 (12.0–20.0)	40.0 ±4.0 ^b 39.5 (35.0–46.0)	45.1 ±3.3 45.5 (41.0–49.0)	< 0.001
CK	215.0 ±7.0 ^a 217.5 (207.0–225.0)	108.3 ±7.4 ^b 108.0 (100.0–118.0)	100.0 ±1.6 100.0 (97.0–102.0)	< 0.001

Variables are shown as mean ± standard deviation, median (minimum-maximum). Statistically significant ($p < 0.05$) when compared with ^aCG group, ^bSUN group.

Statistical analysis was performed using IBM SPSS 22 (IBM SPSS Statistics for Windows, Version 22.0. Armonk, NY: IBM Corp.).

Results

In terms of biochemical results, MDA ($\mu\text{mol/g}$ protein), GSH (nmol/g protein), SOD (U/g protein), and CK (U/l) were compared among the groups (Table I). When the SUN group was compared with the CG group, MDA and CK levels were higher and GSH and SOD levels were considerably lower ($p <$

0.001 , $p < 0.001$, $p < 0.001$, and $p < 0.001$, respectively). When the SUN group was compared with the SUT group, MDA and CK levels were higher and GSH and SOD levels were considerably lower ($p < 0.001$, $p < 0.001$, $p < 0.001$, and $p < 0.001$, respectively). There was no statistically significant difference between SUT and CG ($p = 0.108$, $p = 0.175$, $p = 0.083$, and $p = 0.089$, respectively).

In histopathological analysis, according to the microscopic evaluations of skeletal muscle tissue, the structure and morphology of muscle fibres, their nucleus and blood vessels were normal

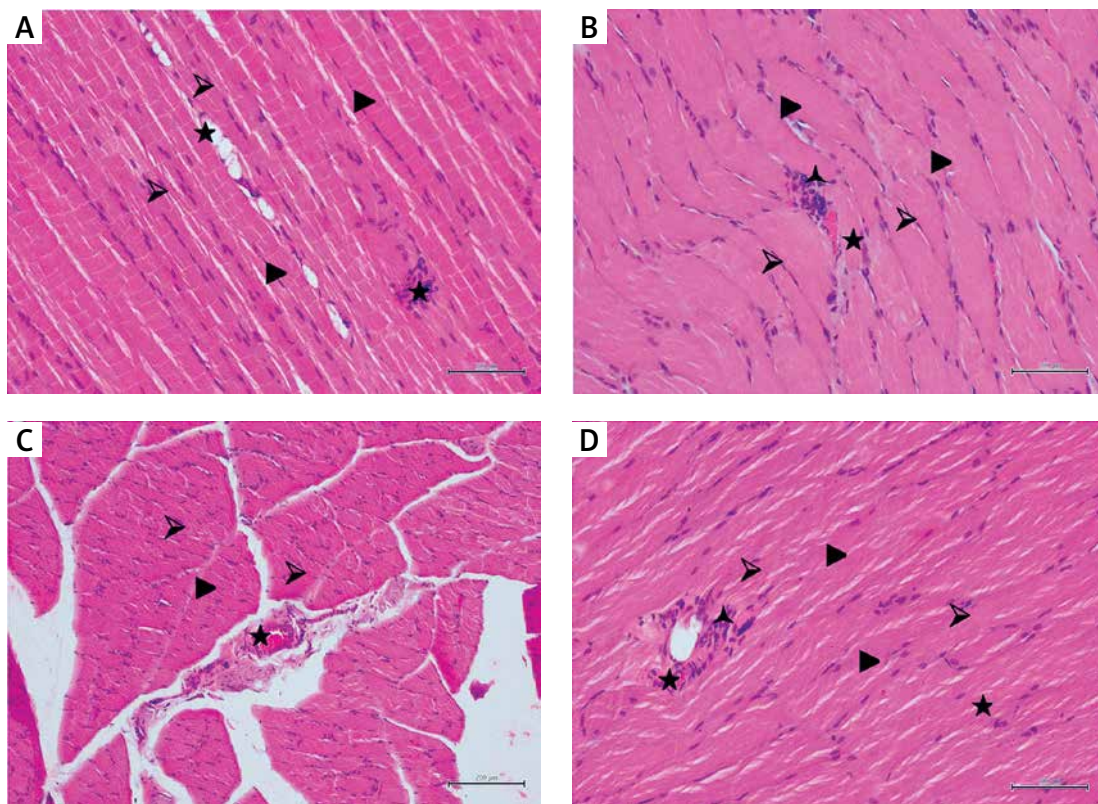


Figure 1. Haematoxylin-eosin staining in skeletal muscle tissue: **A** – in the CG; \blacktriangleright : muscle cell nucleus, \blacktriangleright : muscle fibres, \star : blood vessel, 200 \times ; **B** – in the SUN group; \blacktriangleright : muscle cell nucleus, \blacktriangleright : swollen and irregular muscle fibres, \star : congested blood vessel, \blacktriangle : inflammatory cells, 200 \times ; **C** – in the SUN group; \blacktriangleright : muscle cell nucleus, \blacktriangleright : irregular muscle fibres, \star : congested blood vessel, 100 \times ; **D** – in the SUT group; \blacktriangleright : muscle cell nucleus, \blacktriangleright : regular and normal muscle fibres, \star : blood vessel, \blacktriangle : inflammatory cells, 200 \times

in the control group (Figure 1 A). In the sunitinib group, histological examination revealed irregularities and colour changes in muscle fibres. Degeneration of muscle fibres was revealed by pale and dark areas. Muscle fibres were generally swollen and hypereosinophilic, and some of them showed local hyalinization. A small number of inflammatory cells passed into the tissue. Several adjacent muscle fibres demonstrated degeneration and loss of striations, some of the muscle fibres were ruptured, and blood vessels were congested (Figures 1 B, C). Marked amelioration of muscle tissue was seen in rats treated with taxifolin prior to sunitinib. In this experimental group, sections showed regular alignment and colour of muscle fibres. Spots of inflammatory cells were detected around blood vessels. It was noticed that there was a reduction of rupture in muscle fibres. In addition, blood vessels were normal (Figure 1 D).

Discussion

Chemotherapy applied in cancer treatment can have toxic effects on motor neurons, muscle-nerve junction, and muscle cells [8]. Skeletal muscle toxicity is an important cause of mortality and morbidity [7]. One of the types of drugs used in cancer treatment is tyrosine kinase inhibitors. Tyrosine kinase receptors are transmembrane proteins involved in communication between cells. They are found in many cells and are involved in cell growth, differentiation, and angiogenesis [4]. Tyrosine kinase inhibitors can cause muscle toxicity [5].

Sunitinib is used in cancer treatment. It is one of the drugs that acts as a tyrosine kinase inhibitor [4]. Sunitinib inhibits complex I in mitochondria. As a result of this inhibition, the ROS level in the cell increases. Increasing ROS levels inhibits the AMPK pathway [9]. AMPK pathway inhibition significantly reduces glucose uptake into cells, and insulin resistance occurs as a result [7, 9]. Increasing ROS levels causes mtDNA damage in the mitochondria, mitochondrial dysfunction, and a decrease in the number of mitochondria. It also causes a decrease in ATP production [7].

Sunitinib also activates caspas-3 and caspas-7, which cause apoptosis [9]. Muscle atrophy and muscle weakness occur as a result of apoptosis [7]. Skeletal muscle atrophy is a dose-limiting factor in patients using sunitinib [5]. Oxidative stress is a condition in which cellular antioxidants are insufficient to keep ROS levels below the toxic threshold. This may be due to either excessive ROS production or a decrease in antioxidants, or both [19]. Being a non-enzymatic primary antioxidant, GSH protects cells from oxidative damage by efficiently eliminating lipids and other organic peroxides [20, 21]. Studies have shown that sunitinib reduces the amount of GSH [22].

MDA is the main product of polyunsaturated fatty acid peroxidation and is highly toxic. It causes mutation in deoxyribonucleic acid and irreversible damage to proteins. It is used to measure the degree of oxidative stress and is considered an indicator of ROS [23]. Studies have shown that MDA levels increase as a result of sunitinib use [22]. SOD is an enzyme that converts superoxide radicals to oxygen and hydrogen peroxide [24]. It was observed that the SOD levels of rats treated with sunitinib decreased [25].

The primary role of CK is to aid ATP hydrolysis. It is found in tissues such as skeletal muscle that require high energy. CK is considered to be an indicator of muscle breakdown [26]. Studies have shown that serum CK levels increase after the use of sunitinib [27]. In histopathological examinations, after sunitinib administration, the following were shown: dilated and congested blood vessels filled with red blood cells in the muscle tissue, red blood cells emerging outside the vessel, tissue necrosis findings, cytoplasmic vacuolization, and myofibrillary decrease. It has been stated that the reason for these histopathological findings was the decrease in glutathione in the cell [15, 28].

In the present study, MDA and CK were significantly higher, and SOD and GSH were significantly lower in the SUN group compared with the control group. Histological examinations revealed irregularities in skeletal muscle fibres, degenerative findings, oedema, hyper eosinophilia, and local hyalinization. Signs of inflammation and blood vessel congestion were detected in the muscle tissue. Values obtained after sunitinib administration indicate the formation of oxidative stress and are consistent with previous studies [28].

Taxifolin is a powerful flavonoid found in plants. It has antibacterial, antifungal, anti-inflammatory, analgesic, antipyretic, platelet inhibitor, antioxidant, and anticancer properties. It has been shown that the effects of some antibiotics increase after the use of taxifolin. It increases the effectiveness of the immune system and has been shown to have no side effects [12]. Studies have shown that taxifolin reduces serum MDA and caspas-3,7,8,9 levels, increases SOD and glutathione levels, and has antiapoptotic effects [13, 29]. Taxifolin reduces CK levels. It is protective against ischaemia and reperfusion damage with its antioxidant effect on heart muscle tissue. It prevents inflammation and degeneration of muscle tissue and reduces oedema [13].

In the present study, a significant decrease in MDA and CK values and a significant increase in SOD and GSH values were found in the group administered taxifolin before sunitinib. In histological examination, blood vessels were within normal limits, and a significant decrease in inflammation

was observed. Degenerative findings were not detected in the muscle tissue. It has been determined that taxifolin prevents oxidative stress effects caused by sunitinib use.

In conclusion, sunitinib has toxic effects on muscle tissues. This study supports the hypothesis that taxifolin prevents the toxic effects of sunitinib on muscle tissues both biochemically and histopathologically. As such, taxifolin can be an option to reduce these toxic effects.

Conflict of interest

The authors declare no conflict of interest.

References

- Krause DS, Van Etten RA. Tyrosine kinases as targets for cancer therapy. *N Engl J Med* 2005; 353: 172-87.
- Motzer RJ, Hutson TE, Tomczak P, et al. Overall survival and updated results for sunitinib compared with interferon alfa in patients with metastatic renal cell carcinoma. *J Clin Oncol* 2009; 27: 3584-90.
- Faivre S, Demetri G, Sargent W, Raymond E. Molecular basis for sunitinib efficacy and future clinical development. *Nat Rev Drug Discov* 2007; 6: 734-45.
- Bello CL, Sherman L, Zhou J, et al. Effect of food on the pharmacokinetics of sunitinib malate (su11248), a multi-targeted receptor tyrosine kinase inhibitor: results from a phase I study in healthy subjects. *Anticancer Drugs* 2006; 17: 353-8.
- Gorini S, De Angelis A, Berrino L, Malara N, Rosano G, Ferraro E. Chemotherapeutic drugs and mitochondrial dysfunction: focus on doxorubicin, trastuzumab, and sunitinib. *Oxid Med Cell Longev* 2018; 2018: 7582730.
- Huillard O, Mir O, Peyromaure M, et al. Sarcopenia and body mass index predict sunitinib-induced early dose-limiting toxicities in renal cancer patients. *Br J Cancer* 2013; 108: 1034-41.
- Sorensen JC, Cheregi BD, Timpani CA, Nurgali K, Hayes A, Rybalka E. Mitochondria: inadvertent targets in chemotherapy-induced skeletal muscle toxicity and wasting? *Cancer Chemother Pharmacol* 2016; 78: 673-83.
- Scheede-Bergdahl C, Jagoe RT. After the chemotherapy: potential mechanisms for chemotherapy-induced delayed skeletal muscle dysfunction in survivors of acute lymphoblastic leukaemia in childhood. *Front Pharmacol* 2013; 4: 49.
- Damaraju VL, Kuzma M, Cass CE, Putman CT, Sawyer MB. Multitargeted kinase inhibitors imatinib, sorafenib and sunitinib perturb energy metabolism and cause cytotoxicity to cultured C2C12 skeletal muscle derived myotubes. *Biochem Pharmacol* 2018; 155: 162-71.
- Rice-Evans CA, Miller NJ, Paganga G. Structure-antioxidant activity relationships of flavonoids and phenolic acids. *Free Radic Biol Med* 1996; 20: 933-56.
- Cotelle N. Role of flavonoids in oxidative stress. *Curr Top Med Chem* 2001; 1: 569-90.
- Asmi KS, Lakshmi T, Balusamy SR, Parameswari R. Therapeutic aspects of taxifolin – an update. *J Adv Pharm Education Res* 2017; 7: 187-9.
- Tang Z, Yang C, Zuo B, et al. Taxifolin protects rat against myocardial ischemia/reperfusion injury by modulating the mitochondrial apoptosis pathway. *Peer J* 2019; 7: e6383.
- Zu Y, Wu W, Zhao X, et al. Enhancement of solubility, antioxidant ability and bioavailability of taxifolin nanoparticles by liquid antisolvent precipitation technique. *Int J Pharm* 2014; 471: 366-76.
- Lim AY, Segarra I, Chakravarthi S, Akram S, Judson JP. Histopathology and biochemistry analysis of the interaction between sunitinib and paracetamol in mice. *BMC Pharmacol* 2010; 10: 14.
- Ohkawa H, Ohishi N, Yagi K. Assay for lipid peroxides in animal tissues by thiobarbituric acid reaction. *Anal Biochem* 1979; 95: 351-8.
- Sedlak J, Lindsay RH. Estimation of total, protein-bound, and nonprotein sulfhydryl groups in tissue with ellman's reagent. *Anal Biochem* 1968; 25: 192-205.
- Sun Y, Oberley LW, Li Y. A simple method for clinical assay of superoxide dismutase. *Clin Chem* 1988; 34: 497-500.
- Schulz JB, Lindenau J, Seyfried J, Dichgans J. Glutathione, oxidative stress and neurodegeneration. *Eur J Biochem* 2000; 267: 4904-11.
- Islam MS, Yu H, Miao L, Liu Z, He Y, Sun H. Hepatoprotective effect of the ethanol extract of *Illicium henryi* against acute liver injury in mice induced by lipopolysaccharide. *Antioxidants* 2019; 8: 446.
- Gabryel B, Bontor K, Jarzabek K, et al. Sulodexide up-regulates glutathione S-transferase p1 by enhancing nrf2 expression and translocation in human umbilical vein endothelial cells injured by oxygen glucose deprivation. *Arch Med Sci* 2020; 16: 957-63.
- Imam F, Al-Harbi NO, Khan MR, et al. Protective effect of riva against sunitinib-induced cardiotoxicity by inhibiting oxidative stress-mediated inflammation: probable role of $\text{tgf-}\beta$ and smad signaling. *Cardiovasc Toxicol* 2020; 20: 281-90.
- Del Rio D, Stewart AJ, Pellegrini N. A review of recent studies on malondialdehyde as toxic molecule and biological marker of oxidative stress. *Nutr Metab Cardiovasc Dis* 2005; 15: 316-28.
- Abreu IA, Cabelli DE. Superoxide dismutases—a review of the metal-associated mechanistic variations. *Biochim Biophys Acta* 2010; 1804: 263-74.
- Paech F, Abegg VF, Duthaler U, Terracciano L, Bouitbir J, Krähenbühl S. Sunitinib induces hepatocyte mitochondrial damage and apoptosis in mice. *Toxicology* 2018; 409: 13-23.
- Sumien N, Shetty RA, Gonzales EB. Creatine, creatine kinase, and aging. *Subcell Biochem* 2018; 90: 145-68.
- Adenis A, Bouché O, Bertucci F, et al. Serum creatine kinase increase in patients treated with tyrosine kinase inhibitors for solid tumors. *Med Oncol* 2012; 29: 3003-8.
- Maayah ZH, Ansari MA, El Gendy MA, Al-Arifi MN, Korashy HM. Development of cardiac hypertrophy by sunitinib in vivo and in vitro rat cardiomyocytes is influenced by the aryl hydrocarbon receptor signaling pathway. *Arch Toxicol* 2014; 88: 725-38.
- Sunil C, Xu B. An insight into the health-promoting effects of taxifolin (dihydroquercetin). *Phytochemistry* 2019; 166: 112066.